



PATIENT

Ben Bulman

SPECIES

Feline

BREED

DSH

SEX

Male Neutered

AGE

16 years

WEIGHT

13.7lbs

INTERPRETED BY

Maggie Machen
Lamy, DVM
DACVIM (Cardiology)

IMAGING

PERFORMED BY

Pamela Harrigan,
RDCS

HOSPITAL NAME

Mass Veterinary
Services

REFERRING VET

Dr. Masloski

INVOICE

30208

DATE

4/12/23

PRESENTING CLINICAL SIGNS

History: Ben is referred to evaluate a heart murmur. He is presently doing well at home with a good appetite and good activity level, especially for a feline of his years. On exam: NSR, grade III/VI parasternal murmur, PSS, lung fields clear, mm pink, moist, CRT<2. BP: 150mmHg x 5. *Sedated with propofol for study.

ECHOCARDIOGRAM FINDINGS

2D, m-mode, color flow and Doppler imaging is available.

Left ventricle: The LV diameter is normal with adequate myocardial function. The LV wall thicknesses are mildly increased with regions of irregularity. There is a diffusely hyperechoic endocardium consistent with fibrosis. The papillary muscles are mildly hypertrophied and hyperechoic. The endocardium appears mildly remodeled.

Left atrium: The left atrium is normal. No smoke or thrombi seen.

Mitral valve: The anterior leaflet of the mitral valve appears largely normal. Systolic anterior motion is seen on multimodal imaging. Mild eccentric MR secondary to SAM.

Aortic valve/Aorta: The aortic valve is normal in morphology and mobility. The aortic outflow velocity is normal; however, this is likely affected by sedation. No aortic insufficiency.

Right ventricle: Normal right ventricular diameter and morphology indicating no overt evidence of pulmonary arterial hypertension.

Right atrium: The right atrium is normal in dimension.

Tricuspid valve: The tricuspid valve appears normal with trace tricuspid regurgitation.

Pulmonary valve/Pulmonary artery: The pulmonic valve is normal in morphology and mobility. No pulmonic insufficiency. The RVOT velocity is elevated on color flow suggesting a dynamic obstruction.

Pericardium/other: No pericardial or pleural effusion noted. No obvious cardiac masses.

Heart rhythm: ECG reveals a sinus rhythm with an average HR of 160bpm.

2-Dimensional Measurements

Ao diam (cm)	1.0
LA diam (cm)	1.3
LA:Ao (Swe)	1.3
IVS thickness (cm)	0.63
LVID diastole (cm)	1.3
PW thickness (cm)	0.63
LVID systole (cm)	0.6
FS (%)	54

Doppler Measurements

PV Vmax (m/s)	1.2
AoV Vmax (m/s)	1.6
MR Vmax (m/s)	NA
TR Vmax (m/s)	NA
TR PG (mmHg)	NA

INTERPRETATION OF THE FINDINGS

The diagnosis and cause of the murmur is hypertrophic obstructive cardiomyopathy (HOCM). This indicates some degree of LV thickening (mild in this case) with a dynamic LVOT obstruction (SAM) and secondary MR. There is no left atrial enlargement, indicating the risk for progression to spontaneous CHF and/or a thrombotic event is low. In this normotensive cat, hyperthyroidism should be ruled out as a possible contributing factor. No additional issues are identified.

While no medications have been shown to definitively alter long term outcome at this stage of disease, atenolol is often initiated to decrease the outflow obstruction. In a senior



PATIENT
Ben Bulman

cat without clinical signs or LAE, simple monitoring is advised. Prognosis is guarded given the highly variable rates of progression with subclinical feline cardiomyopathy.

SPECIES
Feline

RECOMMENDATIONS

- Screening BP/T4 every 6 months.
- Anesthetic risk is considered mild, however judicious IV fluid rates are advised to avoid fluid overload. Additionally, drugs that stimulate heart rate should be avoided unless clinically necessary (glycopyrrolate, atropine). Avoid vasodilators as this may worsen the obstruction. A reasonable protocol includes opioid/benzodiazepine premedication, propofol induction, and isoflurane maintenance. Additionally, steroids should be used with caution on older cats, as even a 'normal' geriatric heart can develop evidence of intolerance and fluid retention.
- Monitor for any clinical evidence of cardiac compromise, including respiratory changes and/or signs of a blood clot event (paralysis, neurologic changes, etc.).

BREED
DSH

SEX
Male Neutered

AGE
16 years

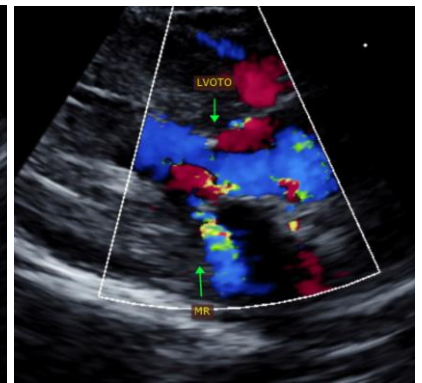
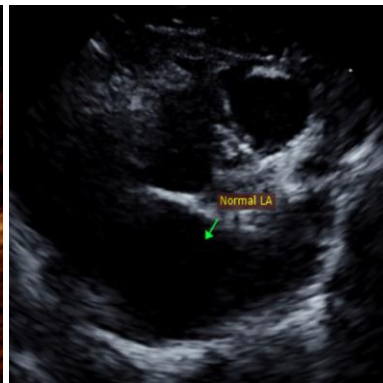
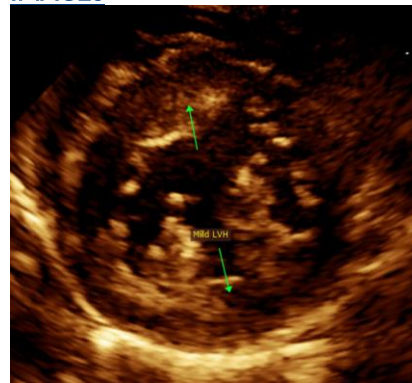
PLAN

- Recommend recheck echocardiogram in 6 months to assess rate of progression, sooner if any issues arise in the interim.

WEIGHT
13.7lbs

IMAGES

INTERPRETED BY
Maggie Machen Lamy, DVM
DACVIM (Cardiology)



IMAGING PERFORMED BY

Pamela Harrigan, RDCS

The information and recommendations provided are based on the images presented by the referring veterinarian. No evaluation can be communicated regarding pathology that was not visible in the image/video clips provided.

HOSPITAL NAME

Mass Veterinary Services

Thank you for this referral. This report was generated using transcription software, and minor dictation errors may be present. If the clinical or image interpretation does not parallel your findings or if I can be of any further assistance, please contact me.

REFERRING VET

Dr. Masloski

Maggie Machen Lamy, DVM
Diplomate of the American College of Veterinary Internal Medicine (Cardiology)
info@sonopath.com

INVOICE
30208

Echocardiogram performed by:

Pamela Harrigan, RDCS
Pet Animal Ultrasound Service (4paus.com)

DATE
4/12/23